

Cardiotoxicity in Breast Cancer Patients: Unveiling Hidden Risks and Evolving Strategies for Cardio-Oncology Care

Nana Gorgiladze^{1,2, ID}, Mata Gujabidze^{3, ID}, Zurab Pagava^{2, ID}, Mikheil Shavdia^{1, ID}

DOI: 10.52340/GBMN.2024.01.01.83

ABSTRACT

Background: Advancements in breast cancer treatment have significantly increased patient survival rates; however, associated treatments, particularly chemotherapy, introduce various side effects. Despite initial categorization as having low or no cardiovascular risk, this case report highlights a 36-year-old breast cancer patient who exhibited notable changes in biomarkers and strain analyses during treatment. The patient, undergoing concurrent chemotherapy and targeted therapy with paclitaxel and Herceptin, experienced alterations in NT pro-BNP levels and global longitudinal strain (GLS) despite maintaining conventional echocardiographic parameters and reporting no symptoms. Prompt initiation of ACE inhibitor treatment resulted in a reduction in NT pro-BNP levels, emphasizing the importance of monitoring and early intervention in breast cancer patients, even those initially considered low cardiovascular risk, to detect and manage potential cardiotoxic effects effectively. This case underscores the need for vigilant surveillance to enhance cardiovascular care and overall treatment outcomes in breast cancer patients.

Keywords: Breast cancer; cardiotoxicity; cardiovascular risk factors; chemotherapy; global longitudinal strain.

INTRODUCTION

Breast cancer treatment has significantly improved, resulting in a higher patient survival rate.¹ Despite these positive outcomes, the treatments, especially chemotherapy, have various side effects.² Thorough follow-up is recommended regarding the initial cardiovascular risk.³ This case report presents the scenario of a young breast cancer patient who, despite being classified as low or no cardiovascular risk, developed significant changes in her biomarkers and strain analyses.

CASE

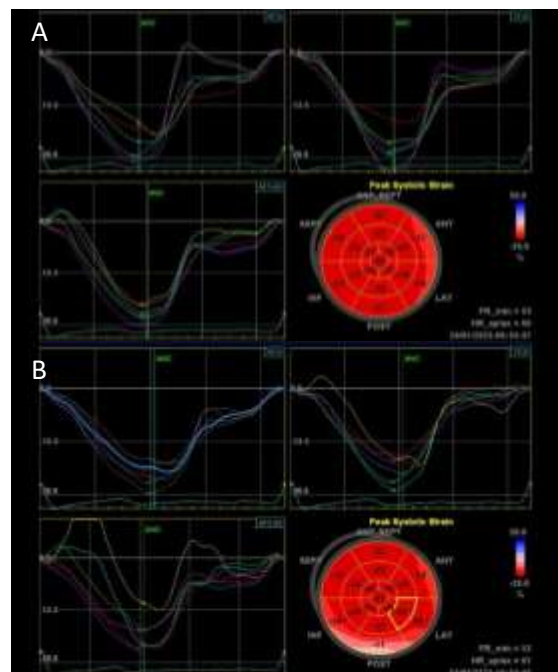
The patient, a 36-year-old woman, was diagnosed with breast cancer, classified as Cr, Mammæ sin. pT1N0M0, 1st Grade 3 II. The tumor had an immunohistochemical profile of ER-positive, PR-positive, and HER2-negative (3+). Oncologic treatment involved concomitant chemotherapy with paclitaxel (80 mg/m²) and targeted therapy with Herceptin (600 mg), administered at 21-day intervals.

At baseline, before chemotherapy, her vital signs and laboratory results were within normal ranges: blood pressure of 110/80 mmHg, heart rate of 68 bpm, GFR of 101, NT pro-BNP of 45 pg/mL, and a BMI of 22.7 kg/m². Echocardiographic parameters also showed normal values, including LVEF at 63%, TAPSE at 25 mm, E/E' at 6, and LVGLS at -26.

During the thorough follow-up period, changes were noted in both NT-proBNP levels and left ventricle global longitudinal strain (LVGLS) values. Following each successive cycle, there was a progression in NT-proBNP concentration, starting from 62.3 pg/mL and reaching 106.2 pg/mL by the 4th cycle of the concurrent administration of paclitaxel (80mg/m²) and Herceptin 600mg injection. This trend continued, culminating

in a 162.9 pg/mL concentration after the 11th injection of Herceptin. These alterations coincided with variations in left ventricular global longitudinal strain (LVGLS) values, which declined from the baseline and continued to fluctuate over subsequent cycles. Specifically, the LVGLS values were noted as -24.8, -20, and -23.6 at the 3rd, 6th, and 11th cycles, respectively. The most significant reduction occurred after three months of treatment, reaching a value of -19.9 (Fig.1).

FIGURE 1. Left ventricular global longitudinal strain at baseline (A) and follow-up (B)



Crucially, the left ventricular ejection fraction (LVEF) and other conventional echocardiographic parameters remained unchanged, and no symptoms were reported during this timeframe.

Following the rise in peptide concentration and subtle yet discernible alterations in strain, a decision was made to commence ACE inhibitor treatment.

Promptly following the initiation of this intervention, at the end of the chemotherapy, the NT pro-BNP level decreased to 87,4 pg/mL, but the LVGLS value remained low.

Despite her initial classification as having no cardiovascular risk, notable changes were evident in both the biomarker levels and strain measurements from the beginning of the treatment.

DISCUSSION

Breast cancer is the most prevalent cancer diagnosed in women worldwide.⁴ Approximately 25% of these cases overexpress the human epidermal growth factor receptor 2 (HER2), a cell surface tyrosine kinase receptor that plays a critical role in tumor aggressiveness and response to targeted therapies.⁵ While trastuzumab (Herceptin) is a cornerstone of treatment for HER2-positive breast cancer, its use, especially when combined with other chemotherapeutic agents, poses a risk of cardiotoxicity. However, the cardiotoxicity risk is reported to be lower in patients treated with trastuzumab without concurrent anthracyclines, with only a 3.2% incidence of left ventricular ejection fraction (LVEF) decline and a 0.5% occurrence of symptomatic heart failure.^{6,7}

Several factors can increase the likelihood of trastuzumab-related cardiotoxicity. These include advanced age, preexisting cardiovascular conditions (e.g., hypertension), lower baseline LVEF, obesity, and prior exposure to anthracycline chemotherapy.⁸⁻¹¹ Moreover, women with breast cancer are at an increased risk of cardiovascular events compared to those without cancer, making cardiovascular surveillance essential during and after cancer treatment.¹²

This case report highlights the importance of vigilant monitoring, even in patients initially classified as low cardiovascular risk. The patient in our case, a young woman without significant cardiovascular history, demonstrated early signs of cardiotoxicity during treatment with paclitaxel and trastuzumab. Despite the absence of symptoms, significant changes in biomarkers (NT-proBNP) and echocardiographic parameters (e.g., global longitudinal strain) were observed early in the treatment course, underscoring the subtle yet critical manifestations of cardiotoxicity associated with these therapies.^{13,14}

CONCLUSIONS

This case report leads to several important conclusions regarding the cardiovascular risks in breast cancer patients undergoing chemotherapy:

- **Cardiovascular monitoring in breast cancer patients:** The case underscores the importance of comprehensive cardiovascular monitoring for breast cancer patients undergoing chemotherapy, even those classified as low cardiovascular risk at the outset;
- **Biomarkers as early indicators:** NT-proBNP levels emerged as a valuable biomarker for the early detection of cardiotoxicity, showing a progressive increase throughout the treatment. Monitoring such biomarkers can provide crucial insights into cardiac function and help guide timely interventions;
- **Strain analysis in cardiotoxicity assessment:** Global longitudinal strain (GLS), particularly LVGLS, was pivotal in identifying early cardiac changes during treatment. Strain analysis offers additional diagnostic value beyond traditional echocardiographic parameters, making it an essential tool in assessing cardiotoxicity;
- **Treatment-induced cardiotoxicity despite low initial risk:** The case highlights that even patients who are initially classified as low or no cardiovascular risk may develop significant cardiotoxicity during cancer treatment. This finding underscores the need for a personalized and proactive approach to care;
- **Importance of individualized cardio-oncology care:** The necessity of individualized cardio-oncology care is evident. The initiation of ACE inhibitor treatment based on changes in biomarkers and strain values exemplifies the importance of tailored interventions to mitigate the risks of treatment-induced cardiotoxicity.

Gaps in knowledge:

- **Optimal timing for intervention:** The case demonstrated the potential of prompt ACE inhibitor therapy following a rise in NT-proBNP levels as an intervention strategy. However, the optimal timing for such interventions to prevent long-term cardiotoxicity remains uncertain and requires further research;
- **Long-term cardiovascular outcomes:** The report concludes at the end of chemotherapy, leaving open questions regarding the patient's long-term cardiovascular outcomes. Future studies that follow patients beyond the treatment period are needed to understand whether cardiotoxic effects persist or resolve over time.

In conclusion, while this case report provides valuable insights into the monitoring and management of cardiotoxicity in breast cancer patients, gaps remain in understanding the full clinical implications and optimal intervention strategies. Further research in this evolving field of cardio-oncology is essential to improving patient outcomes and refining treatment approaches.

AUTHOR AFFILIATIONS

¹ Department of Oncology, Tbilisi State Medical University, Tbilisi, Georgia;

² Department of Cardiology and Pulmonology, Bokhua Memorial Cardiovascular Center, Tbilisi, Georgia;

³ Meta Clinic, Tbilisi, Georgia.

REFERENCES

1. Zhai J, Wu Y, Ma F, Kaklamani V, Xu B. Advances in medical treatment of breast cancer in 2022. *Cancer Innovation*. 2023;2:1-17. doi:10.1002/cai2.46.
2. Bergler-Klein J, Rainer PP, Wallner M, et al. Cardio-oncology in Austria: cardiotoxicity and surveillance of anti-cancer therapies. *Wien Klin Wochenschr*. 2022;134(13-14):654-674. doi:10.1007/s00508-022-02031-0.
3. Lyon AR, López-Fernández T, Couch LS, et al. 2022 ESC Guidelines on cardio-oncology developed in collaboration with the European Hematology Association (EHA), the European Society for Therapeutic Radiology and Oncology (ESTRO) and the International Cardio-Oncology Society (IC-OS). *Eur Heart J*. 2022;43(41):4229-4361. doi:10.1093/eurheartj/ehac244.
4. Cheung YF, Hong WJ, Chan GC, et al. Left ventricular myocardial deformation and mechanical dyssynchrony in children with normal ventricular shortening fraction after anthracycline therapy. *Heart*. 2010;96(14):1137-1141.
5. Slamon DJ, Leyland-Jones B, Shak S, et al. Use of chemotherapy plus a monoclonal antibody against HER2 for metastatic breast cancer that overexpresses HER2. *N Engl J Med*. 2001;344(11):783-792.
6. Tolaney SM, Barry WT, Dang CT, et al. Adjuvant paclitaxel and trastuzumab for node-negative, HER2-positive breast cancer. *N Engl J Med*. 2015;372(2):134-141.
7. Dang C, Guo H, Najita J, et al. Cardiac outcomes of patients receiving adjuvant weekly paclitaxel and trastuzumab for node-negative, ERBB2-positive breast cancer. *JAMA Oncol*. 2015;2(1):29-36.
8. Cardinale D, Sandri MT, Colombo A, et al. Prognostic value of troponin I in cardiac risk stratification of cancer patients undergoing high-dose chemotherapy. *Circulation*. 2004;109(22):2749-2754.
9. Guenancia C, Lefebvre A, Cardinale D, et al. Obesity as a risk factor for anthracyclines and trastuzumab cardiotoxicity in breast cancer: a systematic review and meta-analysis. *J Clin Oncol*. 2016;34(26):3157-3165.
10. Litvak A, Batukbhai B, Russell SD, et al. Racial disparities in the rate of cardiotoxicity of HER2-targeted therapies among women with early breast cancer. *Cancer*. 2018;124(9):1904-1911.
11. Henry ML, Niu J, Zhang N, et al. Cardiotoxicity and cardiac monitoring among chemotherapy-treated breast cancer patients. *JACC Cardiovasc Imaging*. 2018;11(8):1084-1093.
12. Gernaat SA, Boer JM, van den Bongard DH, et al. The risk of cardiovascular disease following breast cancer by Framingham risk score. *Breast Cancer Res Treat*. 2018;170(1):119-127. doi:10.1007/s10549-018-4723-0.
13. Osman M, Elkady M. A prospective study to evaluate the effect of paclitaxel on cardiac ejection fraction. *Breast Care (Basel)*. 2017;12(4):255-259. doi:10.1159/000471759.
14. de Azambuja E, Ponde N, Procter M, et al. A pooled analysis of the cardiac events in the trastuzumab adjuvant trials. *Breast Cancer Res Treat*. 2020;179(1):161-171.